

PET und PET/MRT – Sensitive Frühdiagnostik von vaskulären Erkrankungen

Henryk Barthel

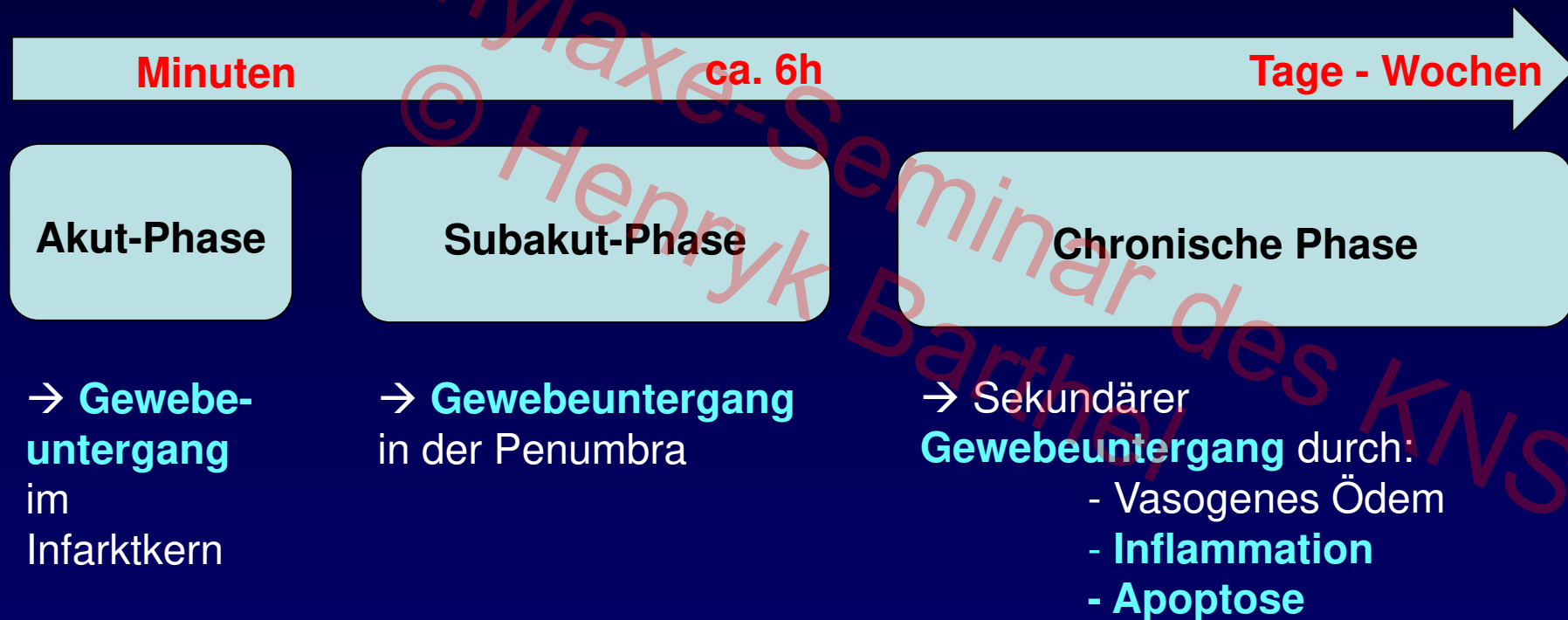
Klinik und Poliklinik für Nuklearmedizin
(Direktor: O. Sabri)
Universitätsklinikum Leipzig

7. Prophylaxe-Seminar des Kompetenznetzes Schlaganfall, Berlin, 03.12.16

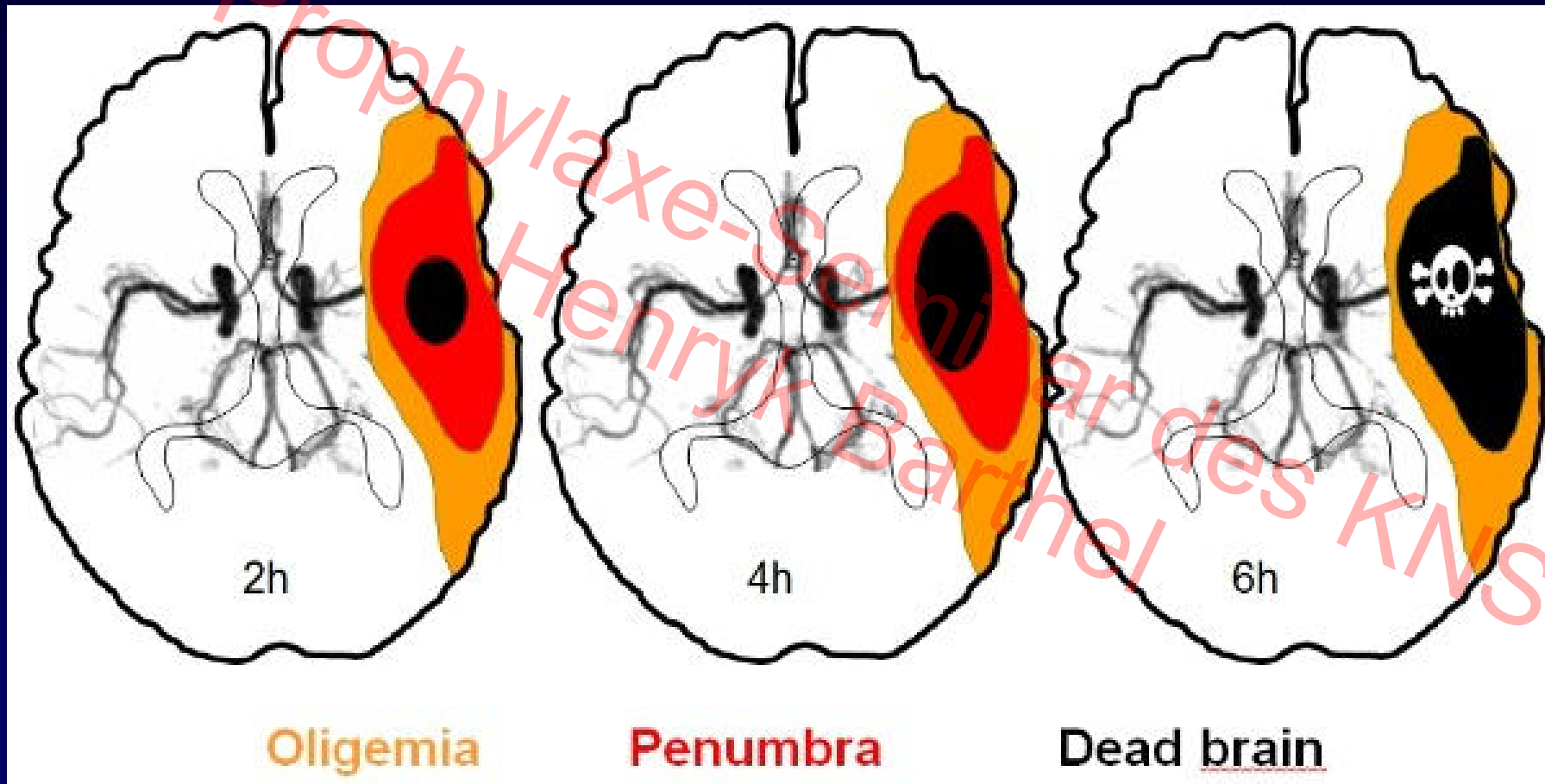
7.

- Einleitung
- PET/MRT-Methodik
- Akuter Schlaganfall präklinisch
- Akuter Schlaganfall klinisch
- Andere zerebrovaskuläre Erkrankungen
- Arteriosklerose
- Zusammenfassung

Hirnfarkt-Progression



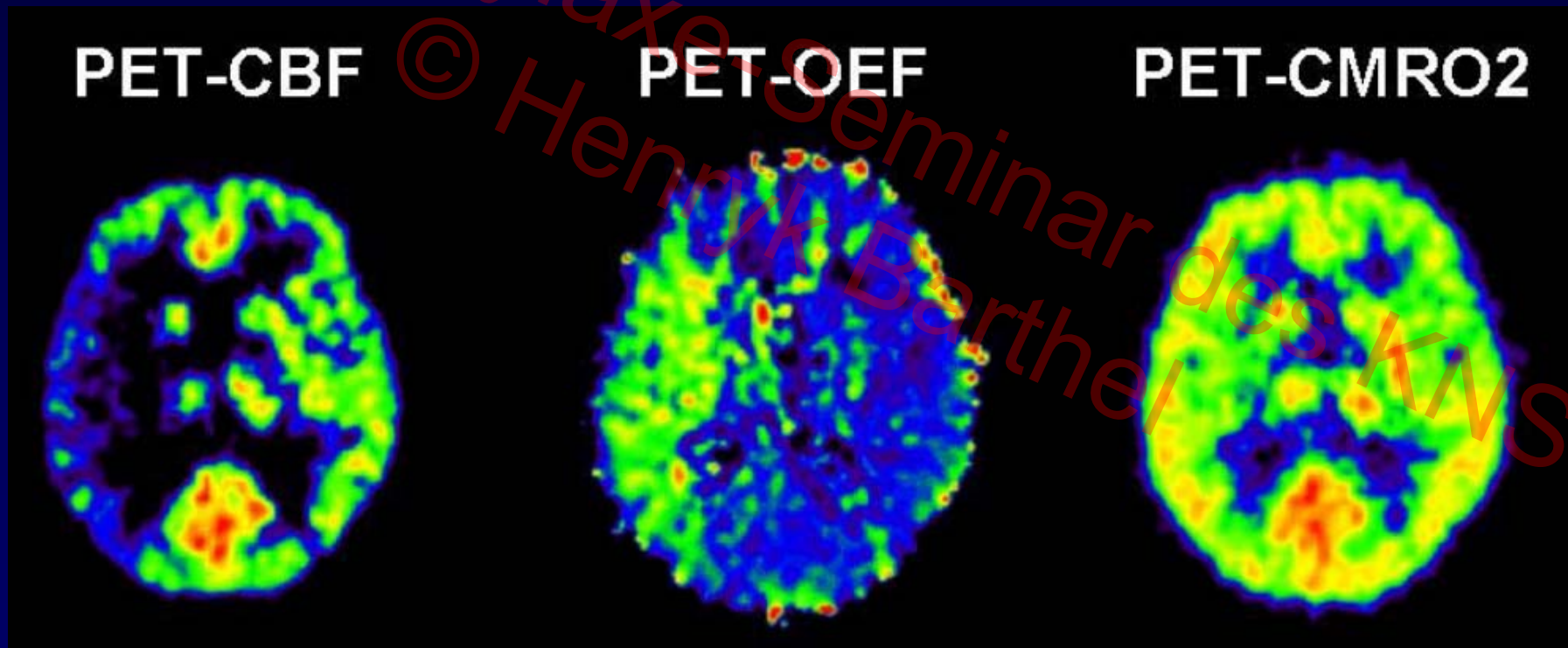
Ischämische Penumbra



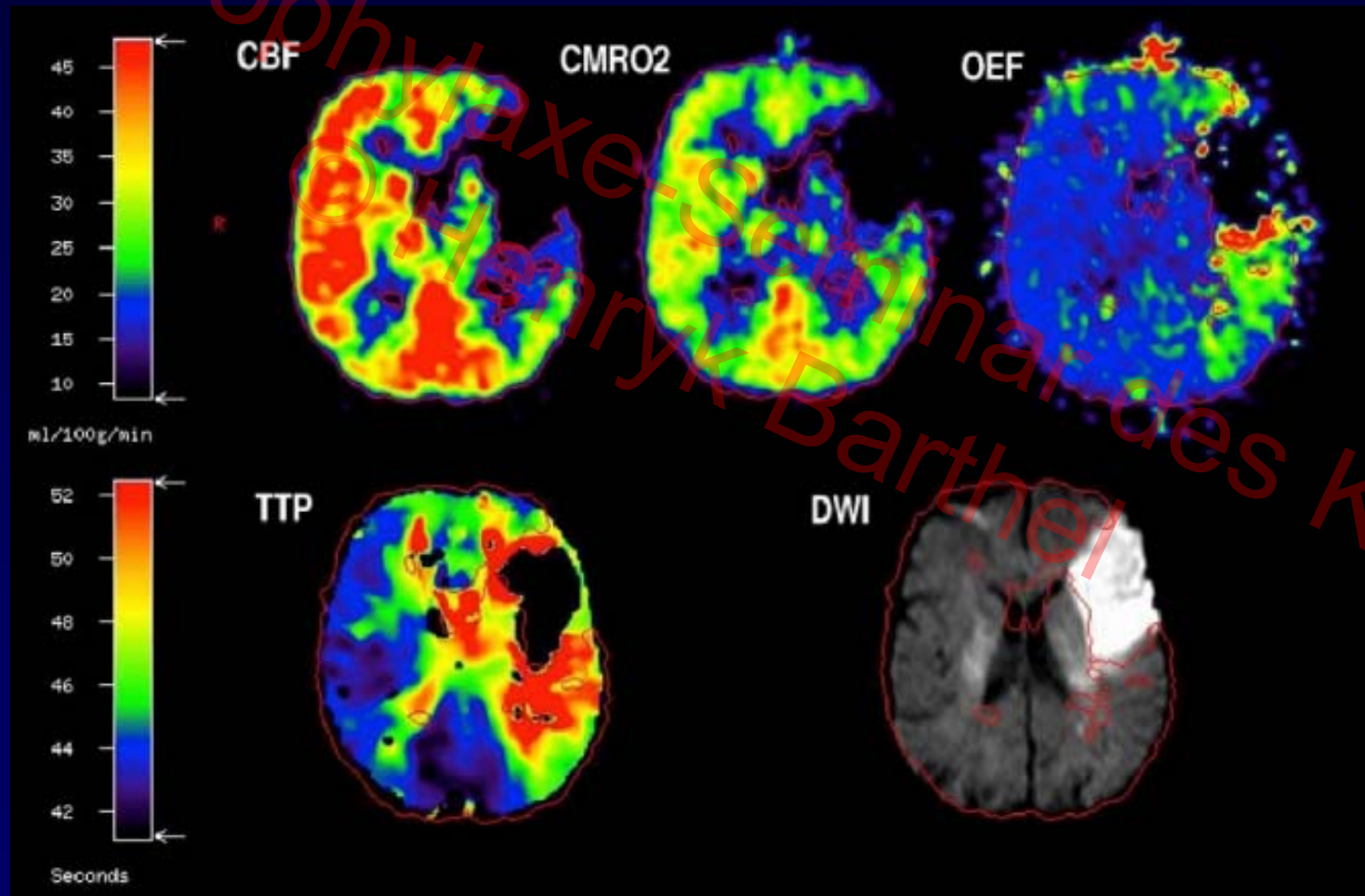
12-22 ml/100g/min



PET beim akuten ischämischen Schlaganfall



PET und MRI beim akuten ischämischen Schlaganfall

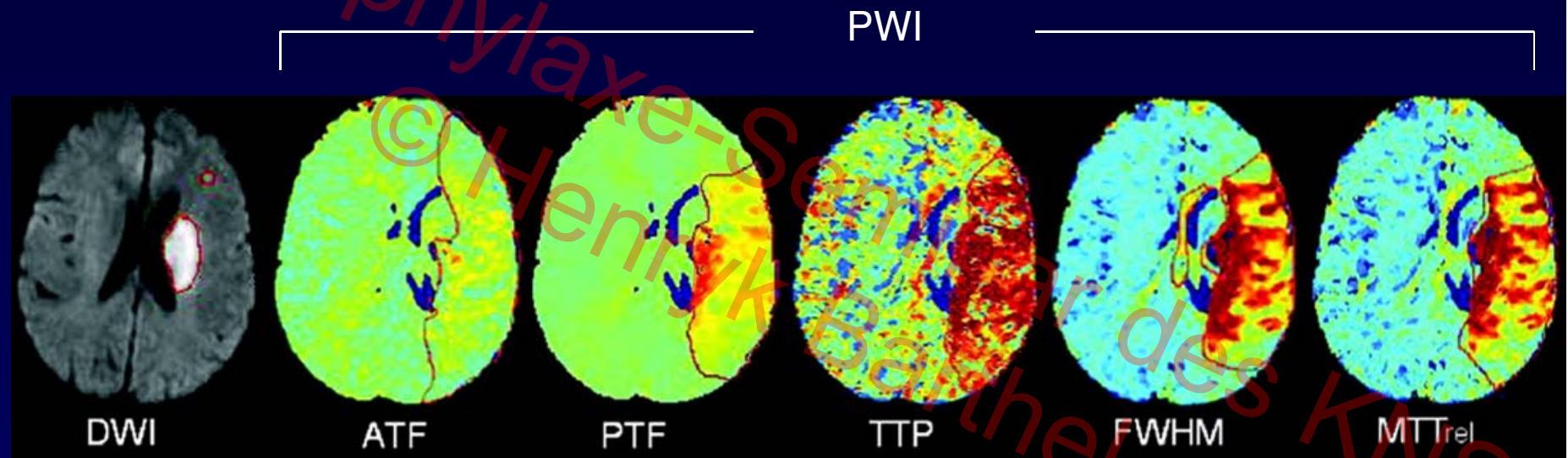


Heiss & Zarow Weber, *J Nucl Med* 2016



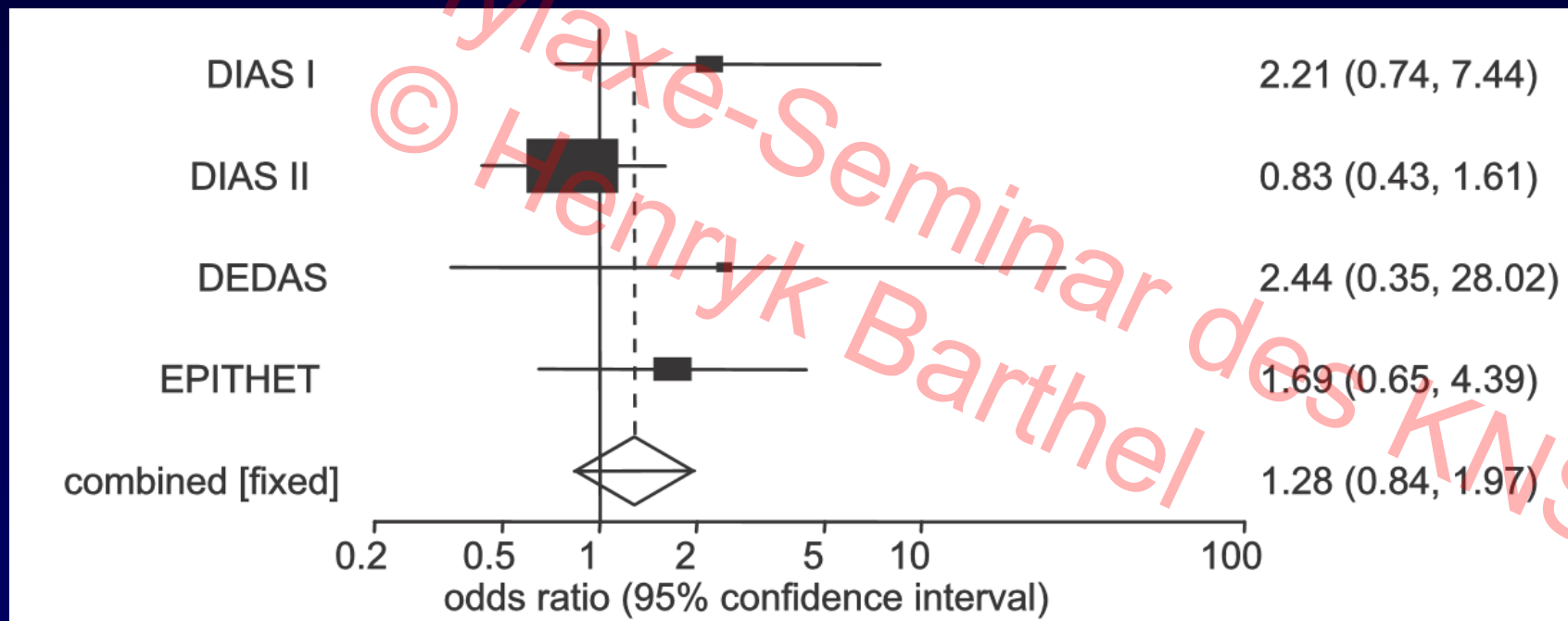
UNIVERSITÄT LEIPZIG

MRT-DWI/PWI-Mismatch-Konzept



PWI in Abhängigkeit vom errechneten Parameter sehr variabel

MRT-Mismatch-basierte iv- Thrombolyse



→ Verbesserte Rekanalisation, aber keine
Verbesserung des klinischen Outcomes

Bildgebungsgesteuerte endovaskuläre Schlaganfalltherapie

Studie	Bildgebung	Therapie*-Fenster	Outcome
MR CLEAN ¹	Angiographie	<6hrs	Positiv
ESCAPE ²	CT, CTA	<12hrs	Positiv
EXTEND-IA ³	Perfusions-CT	<4,5hrs	Positiv
SWIFT-PRIME ⁴	DWI-PWI MRT	<6hrs	Positiv
REVASCAT ⁵	Perfusions-CT/DWI-PWI MRT	<8hrs	Positiv

*Thrombektomie + iv-Alteplase

¹Berkhemer et al., *N Engl J Med* 2015

²Goyal et al., *N Engl J Med* 2015

³Campbell et al., *N Engl J Med* 2015

⁴Saver et al., *N Engl J Med* 2015

⁵Jovin et al., *N Engl J Med* 2015

PET/MRT = Synergistisch

Improvement of PET within combined PET/MRI

- Anatomical affiliation of PET signal
- Movement correction
- Partial volume effect correction
- Tracer uptake quantification
- MRI-derived input function

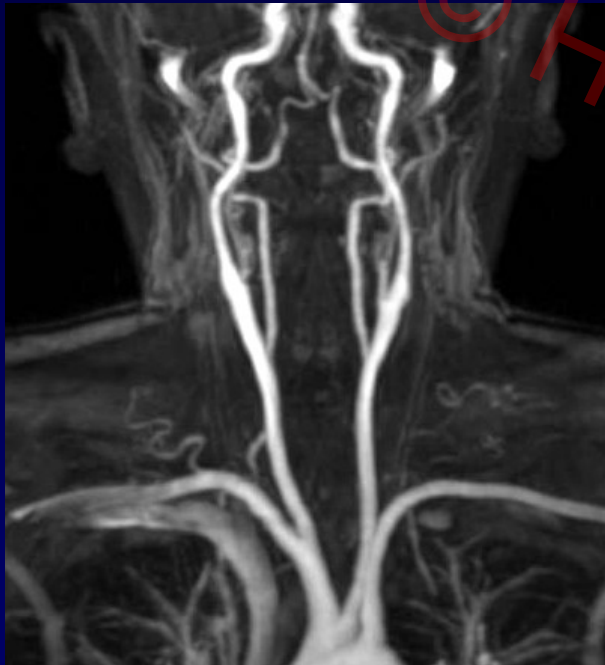
Improvement of MRI within combined PET/MRI

- Cross-evaluation of new MRI techniques* against gold standard PET techniques

*CBF, OEF etc.

Bilddaten-Basierte Arterielle Inputfunktion


→ MR angiography (TOF), vessel segmentation -> PET overlay



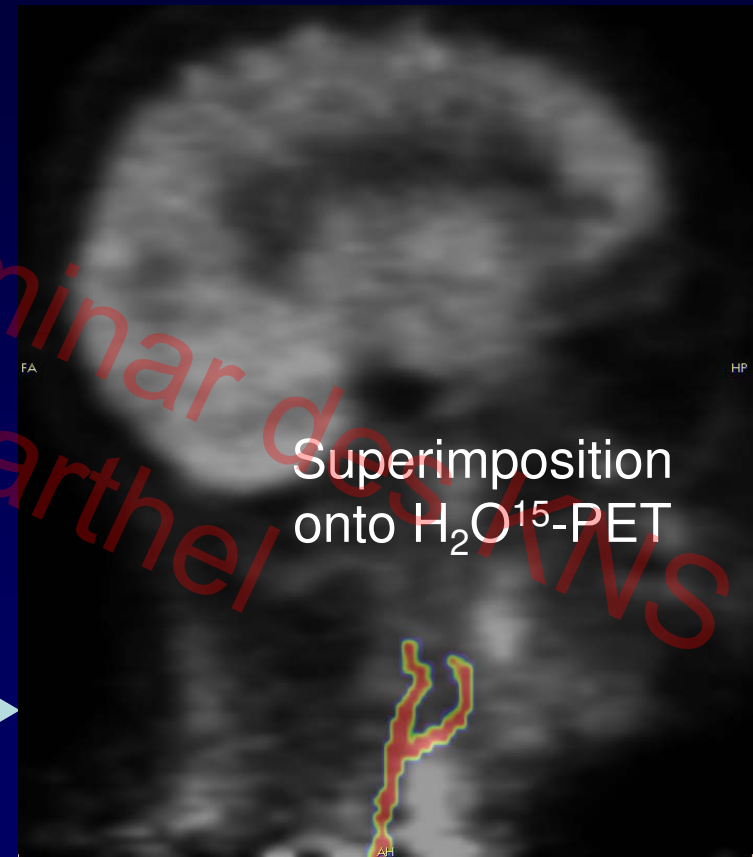Fast gradient echo
sequence (TOF-MRI)

Bilddaten-Basierte Arterielle Inputfunktion

7. Prophylaxe-Seminar des MWS
© Henryk Barthel

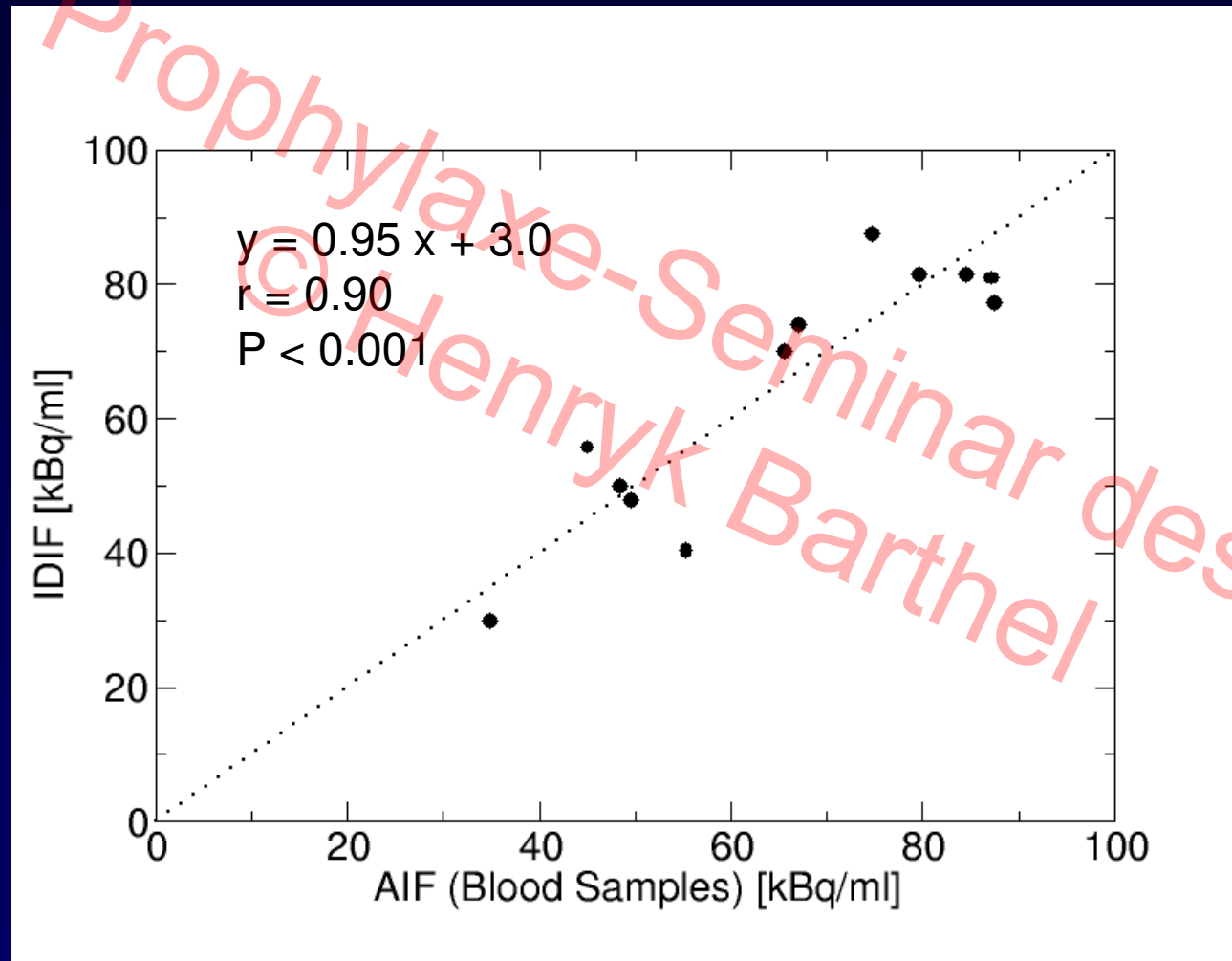


Resampling
Segmentation



Fast gradient echo
sequence (TOF-MRI)

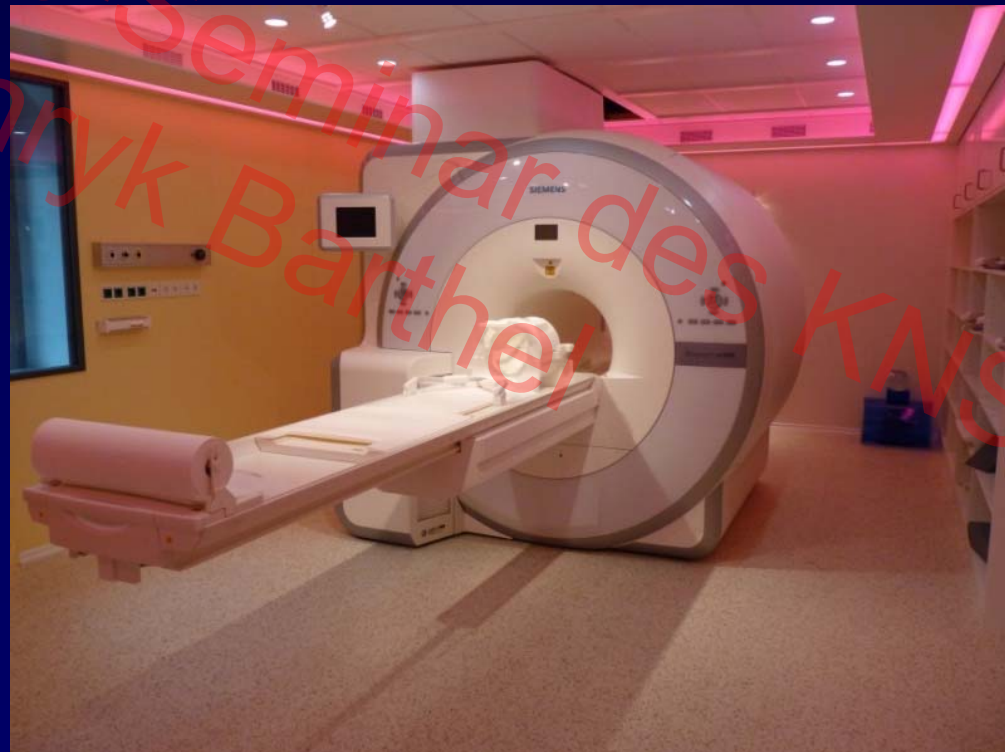Bilddaten-Basierte Arterielle Inputfunktion



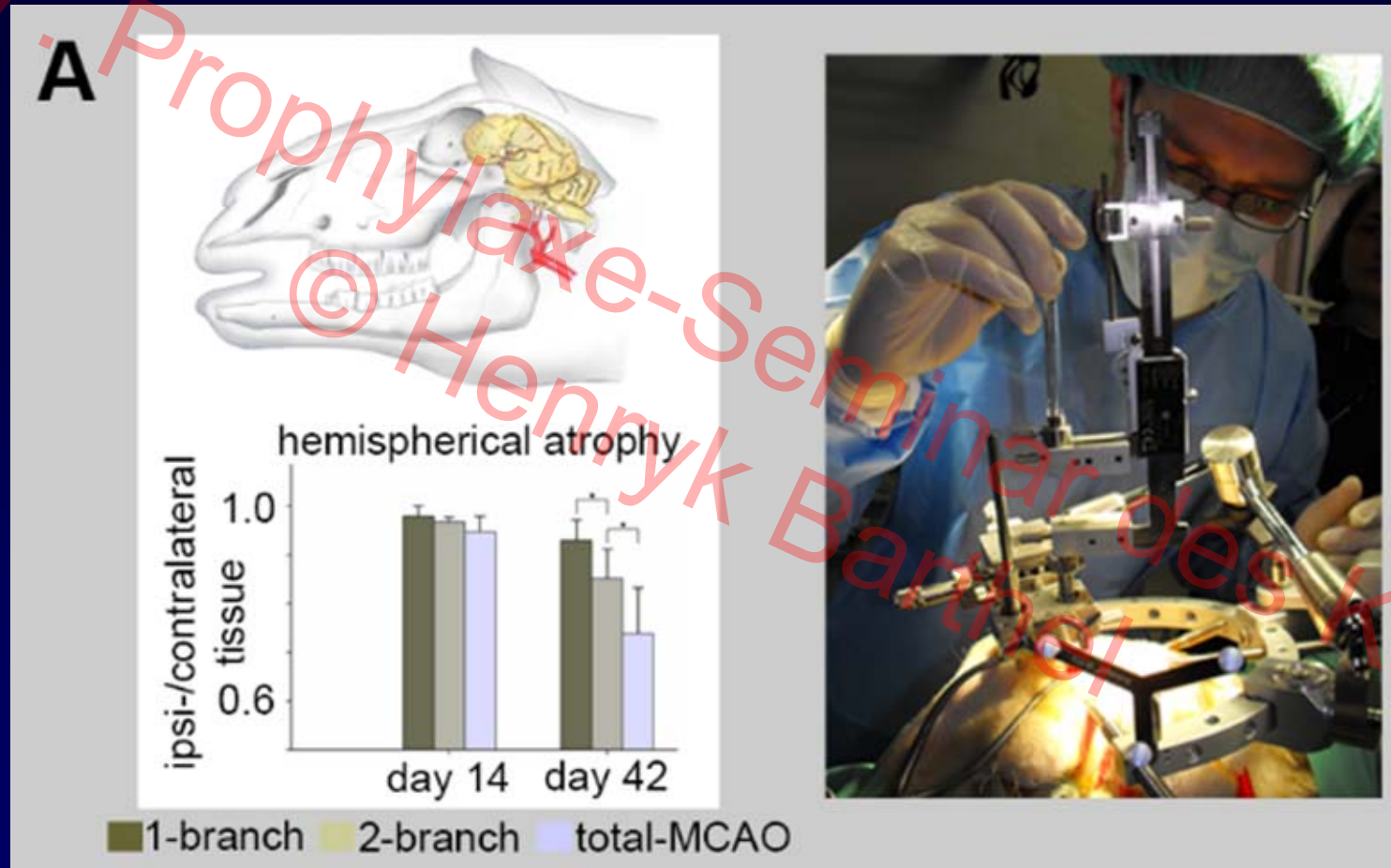
Schlaganfall-PET/MRT in Leipzig

- Worldwide first study using simultaneous PET/MRI
J Cereb Blood F Metab 2016
- Testing of Arterial Spin Labeling (ASL) MRI in this context
Neurology 2016
- Ongoing human and preclinical (sheep model) trials

Integrated PET/MRI system
no. 4 worldwide, funded by
German Research
Council/Max Planck Society,
installed in 2011



Schaf-Schlaganfall-Modell I

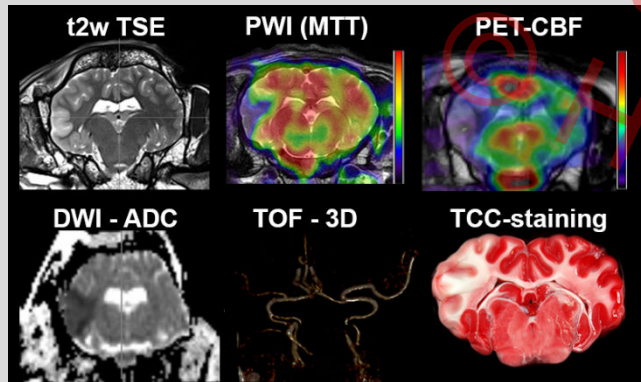


Transcranial approach for permanent and transient middle cerebral artery occlusion (MCAO)

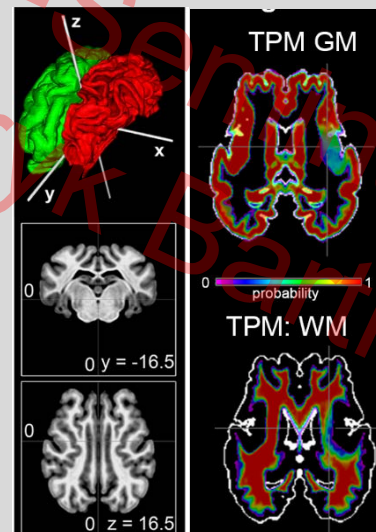
Frameless stereotactic device for intracerebral cell application or induction of cerebral hemorrhage

Schaf-Schlaganfall-Modell II

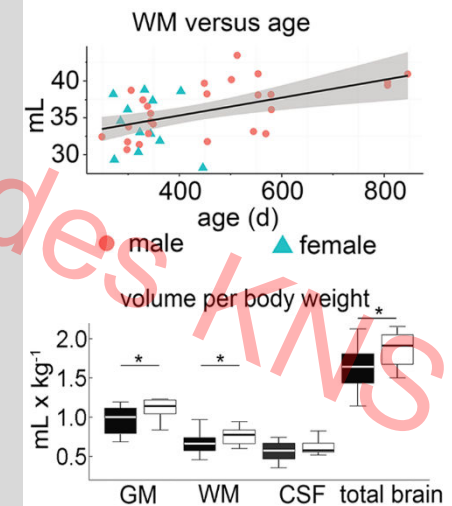
Scanner data (MRI, PET, PET-MR)



Automatic processing in stereotactic space with and without computational lesion model

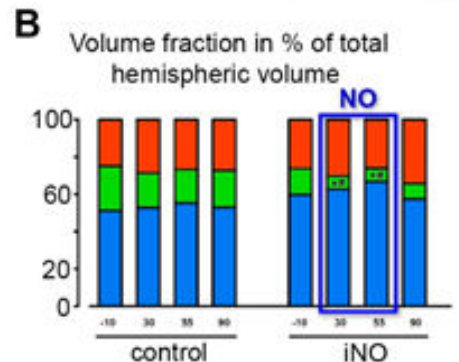
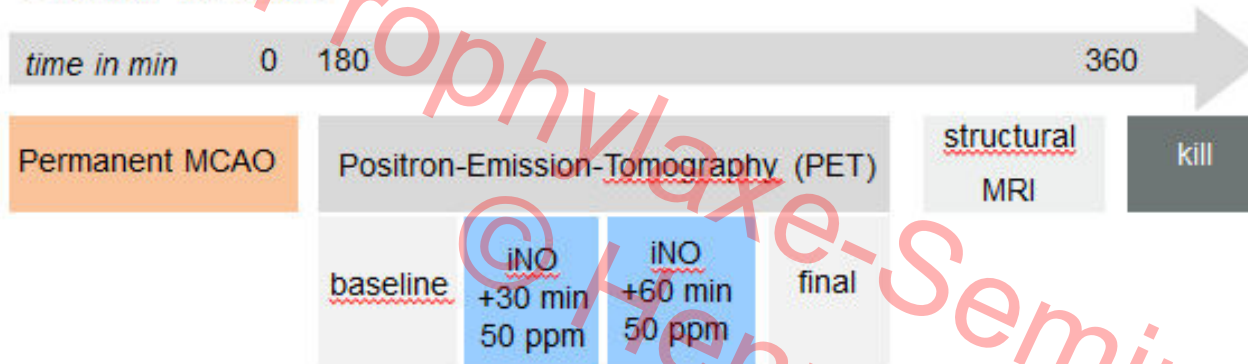


Reproducible, objective (atlas-based) analyses



Inhalatives NO - Positiver Einfluss auf Penumbra

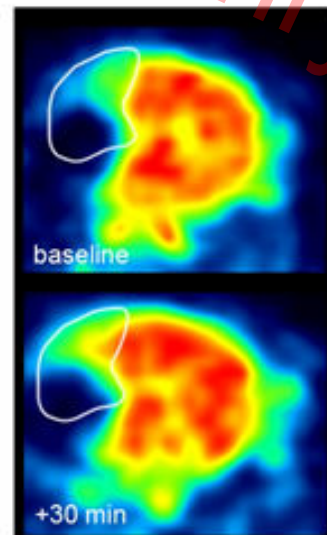
Study design



■ > 22mL / min x 100g brain tissue

■ 8 - 22mL / min x 100g brain tissue

■ < 8mL / min x 100g brain tissue



Effectivity:

- Temporary reduction of penumbra in favor of normally perfused brain tissue, no effect on core

Safety

- Approach is safe (but: transiently elevated Met-Hb)
- No secondary hemorrhage (T2*), no blood pressure drops, normal peripheral circulation

Inhalatives NO – Geplante PET/MRT-gestützte Studie

Prophylaxe Seminar des KNS
© Henryk Barthel

Universitätsklinikum Leipzig
Anstalt öffentlichen Rechts
UNIVERSITÄT LEIPZIG
Medizinische Fakultät

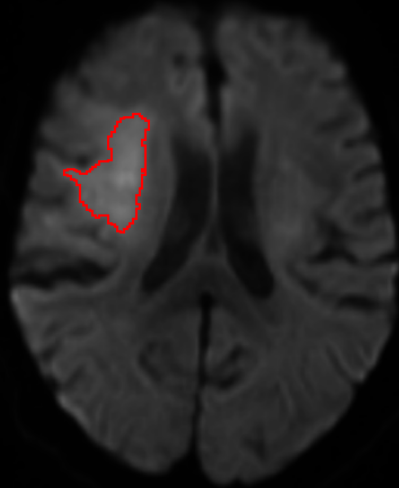
Fraunhofer
EMB

LMU **KLINIKUM** **CAMPUS GROSSHADERN**
DER UNIVERSITÄT MÜNCHEN **INSTITUT FÜR SCHLAGANFALL- UND DEMENZFORSCHUNG**

Schlaganfall-PET/MRT in Leipzig

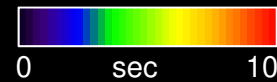
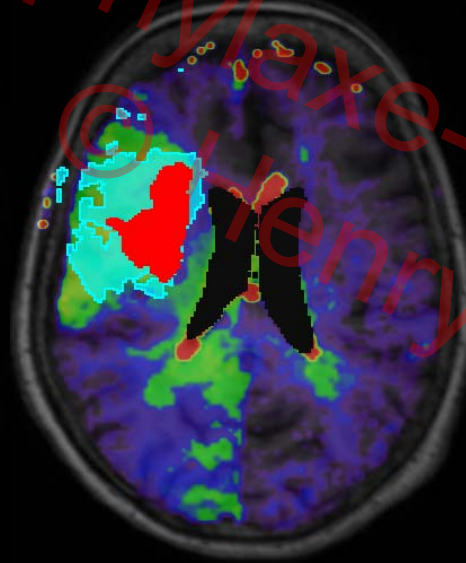
Infarction core

Diffusion-weighted MRI (DWI)




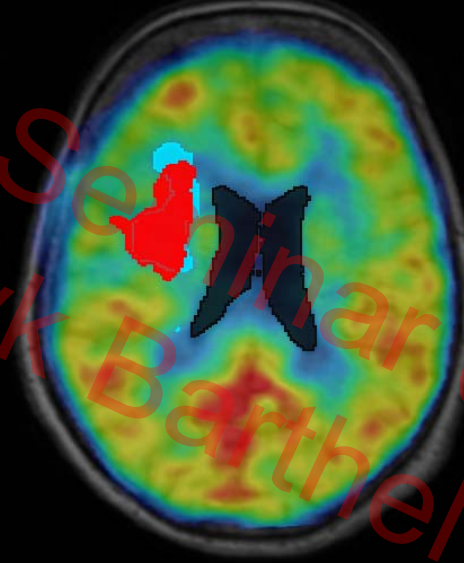
MR penumbra

MR contrast media dynamics (T_{max})



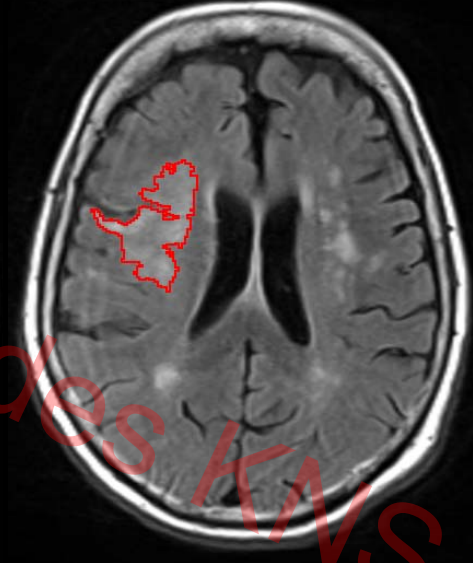
PET penumbra

"Gold standard" CBF as determined by H_2O kinetic modeling



Outcome*

FLAIR MRI day 6



Infarction core (DWI)

Penumbra ($T_{max} > 4\text{sec}$)

Infarction core (DWI)

Penumbra (CBF $< 0.2\text{ml/g/min}$)

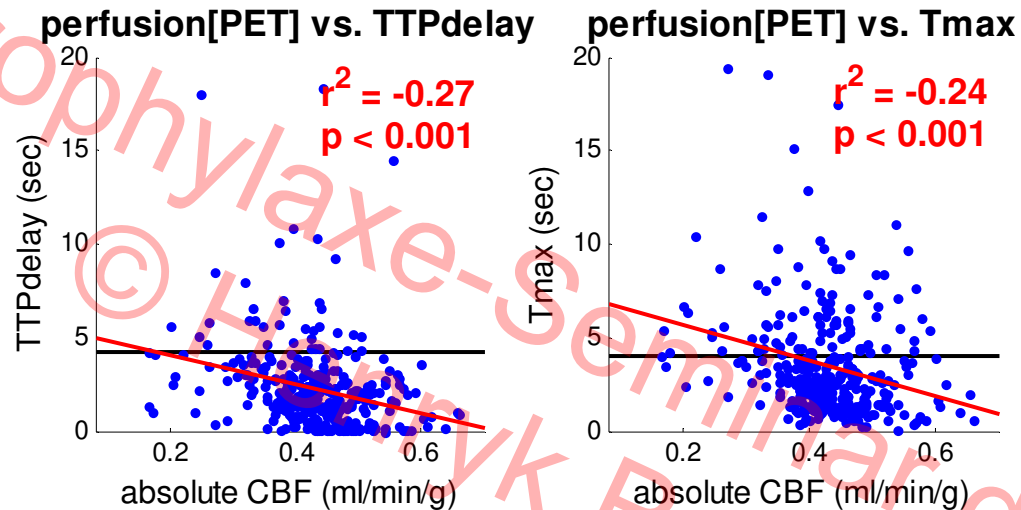
Infarction core (DWI)

Final infarction

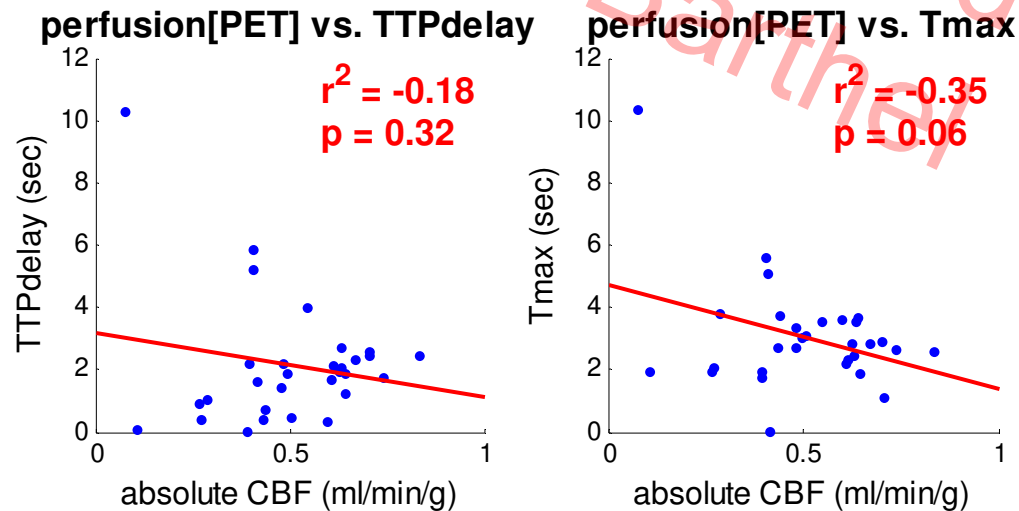
*Without specific treatment

Schlaganfall-PET/MRT in Leipzig

- Humans



- Animals

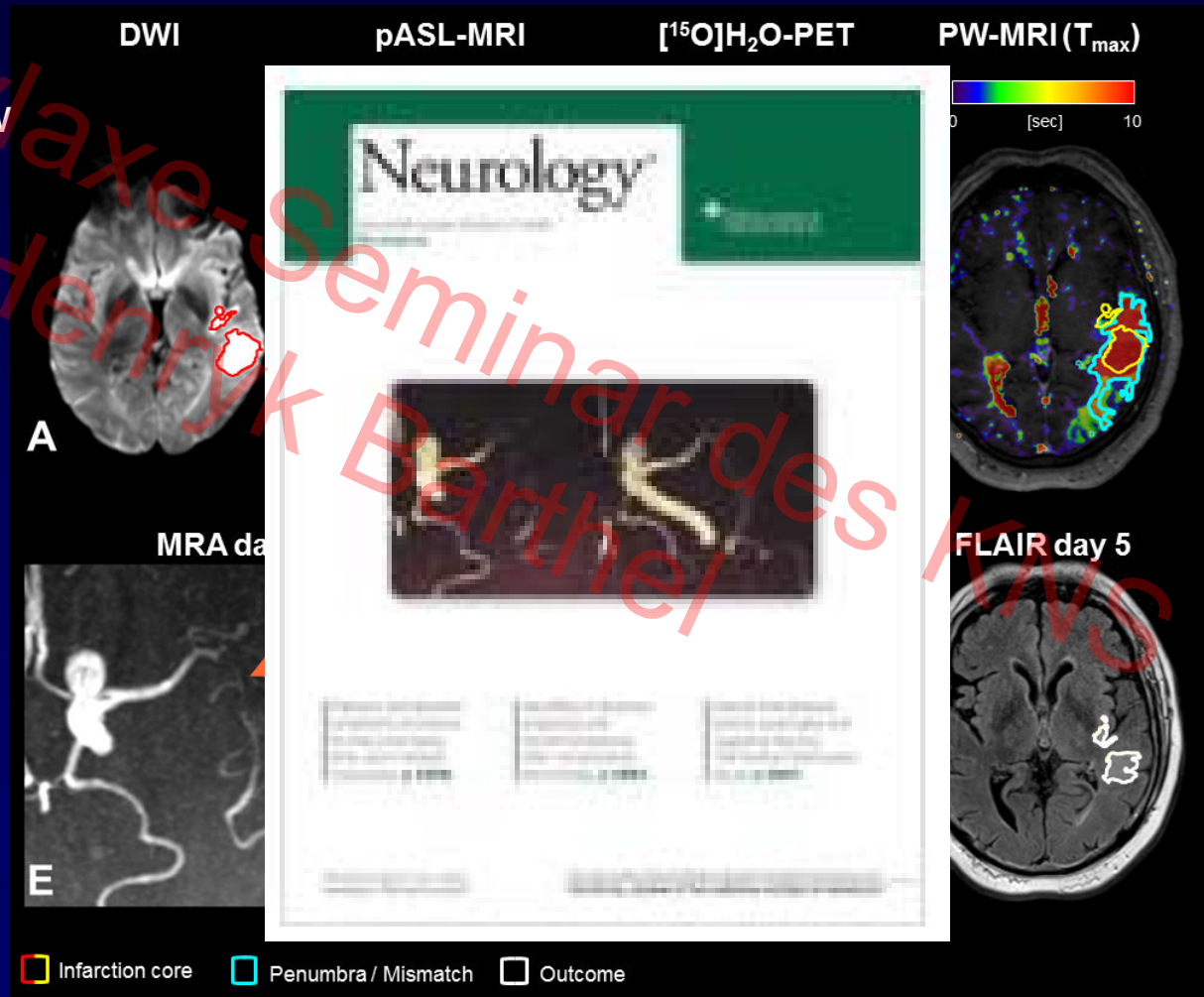


Schlaganfall-PET/MRT in Leipzig

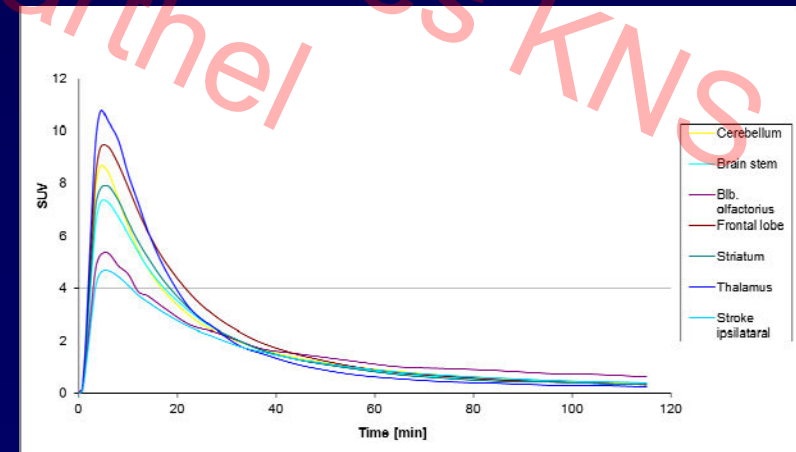
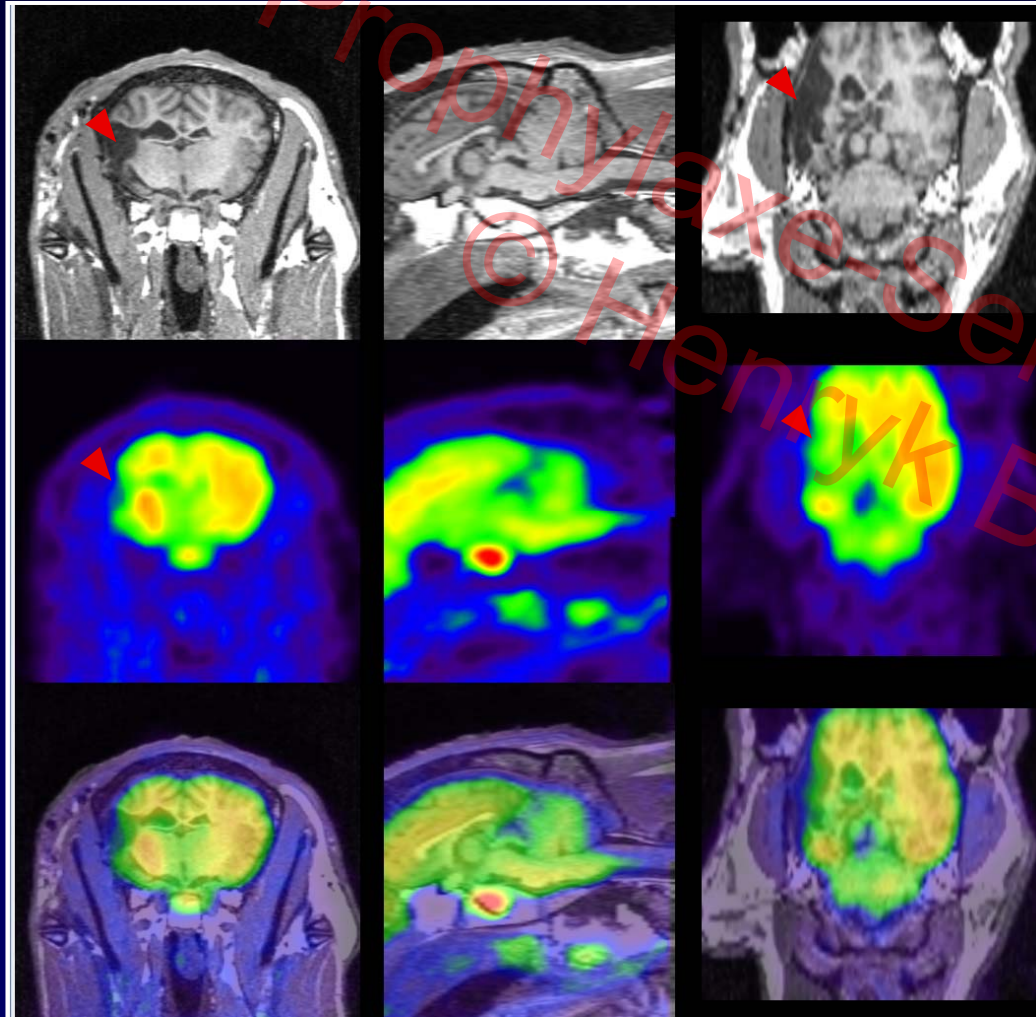
Imaging 5.5h after onset of aphasia

- PET confirmation:
 - (1) Insufficient collateral flow
 - (2) Target mismatch
- Unexpected:
 - (1) Spontaneous recanalization of left middle cerebral artery
 - (2) No worsening without therapy


→ PET/MRI may improve the understanding of stroke pathophysiology



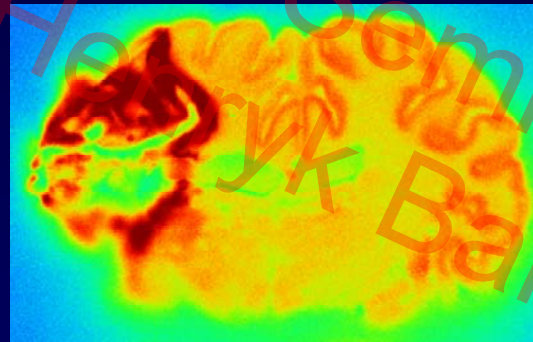
PET/MRT von Neuroinflammation nach Schlaganfall



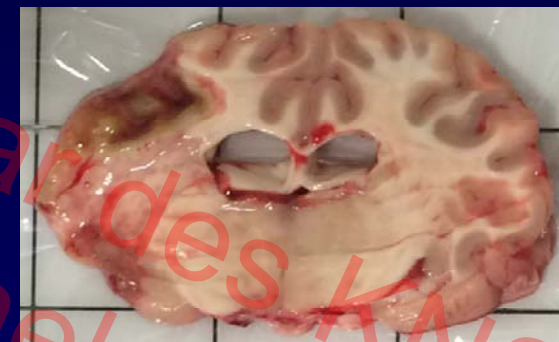PET/MRT von Neuroinflammation nach Schlaganfall



PET 110-120min p.i.



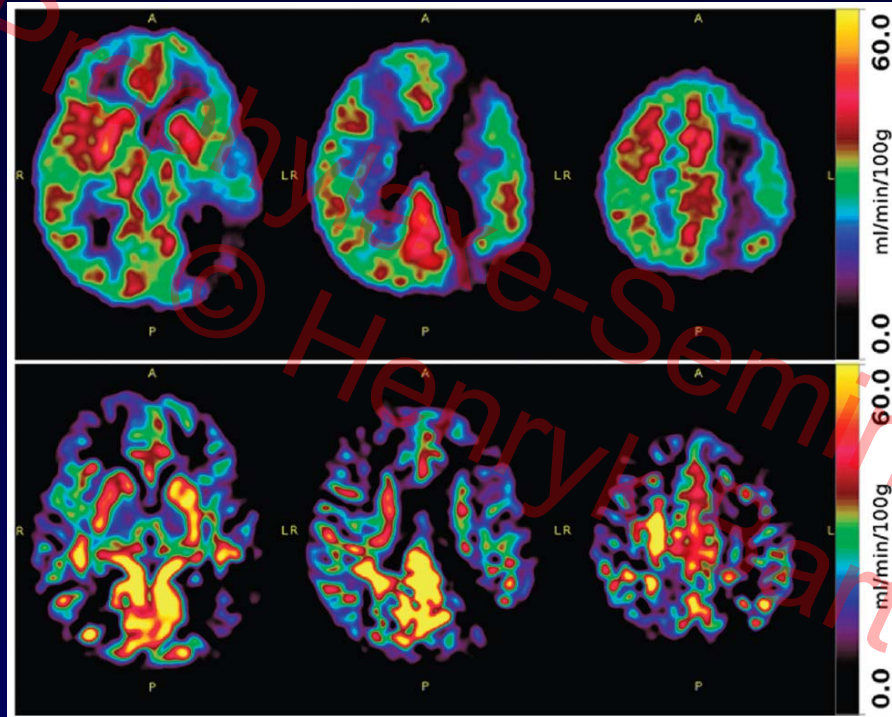
Autoradiographie



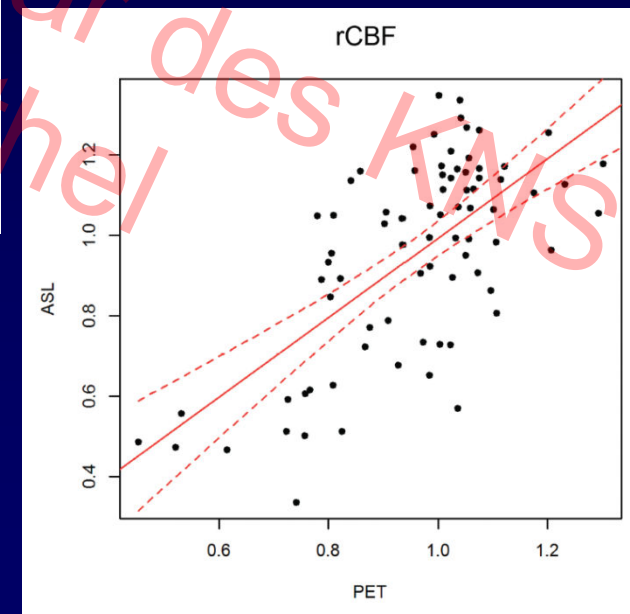
Hirnschnitt

CBF PET und MRI bei Moyamoya-Disease

[¹⁵O]H₂O PET

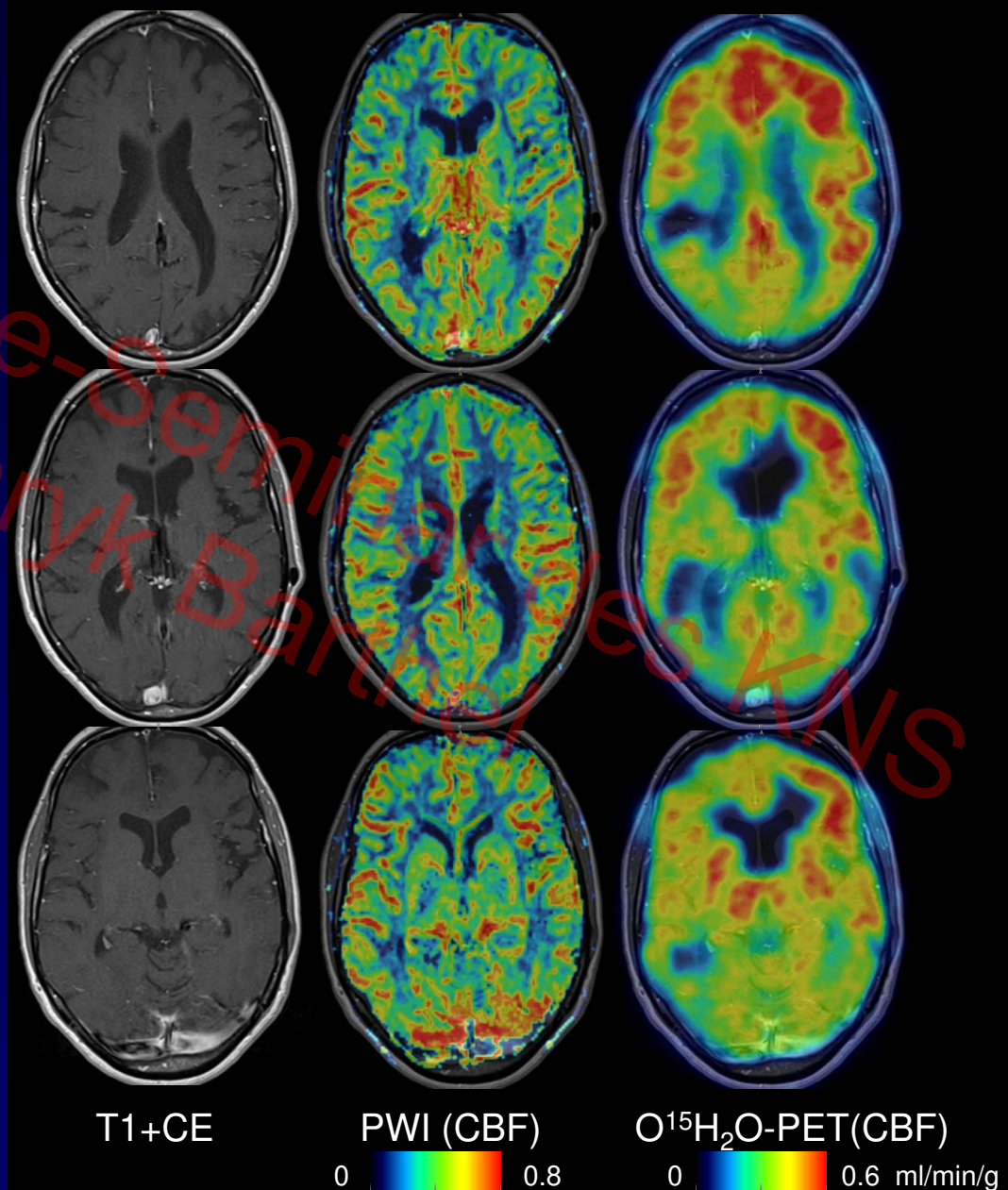


ASL MRI



PET/MRT bei Neuro-Lupus Erythematoses

- 47, female
- Systemic LE
- Raynaud syndrome
- First onset of epileptic seizures
- ANA titer of 1: 160
- Anti-histone ABs pos.
- MRA without signs of vasculitis



PET/MRT von Atherosklerose

Utility of Combining PET and MR Imaging of Carotid Plaque



Alex T. Vesey, MD^a, Marc R. Dweck, MD, PhD^{a,b,c},
Zahi A. Fayad, PhD^{b,c,*}

Table 2
Examples of molecular and structural PET and MR imaging targets in carotid atherosclerosis: complementarity and potential for cross validation

Process	Target	PET Radiotracer	MR Technique (Molecular or Structural)
Inflammation/cell recruitment	VCAM-1	—	VCAM-1-BP + USPIO ⁵³
	ICAM-1	—	VCAM-1-BP + Gd ⁵⁴
	Glycolysis	[18F]-FDG ^{10,56}	ICAM-1 ligand + MPIO ⁵⁵
	TSPO receptor	[11C]-PK11195 ¹¹	—
	Macrophage scavenger receptor	[124I]-CD86-Fc ⁵⁷	SR-A1 ligand + USPIO ⁵⁸
	Somatostatin Receptor 2	[68Ga]-DOTATATE ⁵⁹	—
Phagocytosis	—	—	Unconjugated USPIO ⁶⁰
	—	—	Emulsified perfluorocarbons ³⁹
Matrix and proteinases	MMP	Various ⁶¹	P947 + Gd ⁶²
	Elastin	—	BMS753951 + Gd ⁶³
Lipid-rich core	Lipid pool	—	LDL particles + Gd ⁶⁴
	Hypoxic cells	[18F]-FMISO ⁶⁵ [18F]-FDG ⁶⁶	—
Cell death	Phosphatidylserine	—	Phosphatidylserine targeting peptide + Gd ⁶⁷
	Caspase 3 activity	[18F]-CP18 ⁶⁸	—
Angiogenesis	$\alpha_v\beta_3$ -integrins	[18F]-galacto-RGD ⁶⁹	RGD-peptide mimetic + Gd ⁷⁰
	Neovessels	—	DCE-MR imaging
Intraplaque hemorrhage	Methemoglobin	—	Multicontrast MR imaging ^{71,72}
Calcification process	Active micro-calcification	[18F]-Fluoride ¹²	—
Thrombosis	Fibrin	[64Cu]-EP-2104R ³²	EP-2104R + Gd ^{32,73}
		[64Cu]-FPB ⁷⁴	—

Abbreviations: BP, binding protein; DCE, delayed contrast enhancement; FMISO, fluoromisonidazole; Gd, gadolinium; ICAM, intercellular adhesion molecule; LDL, low-density lipoprotein; MMP, matrix metalloproteinase; TSPO, translocator protein; USPIO, ultrasmall superparamagnetic iron oxide; VCAM, vascular cell adhesion molecule.

PET/MRT und Schlaganfall-Risiko

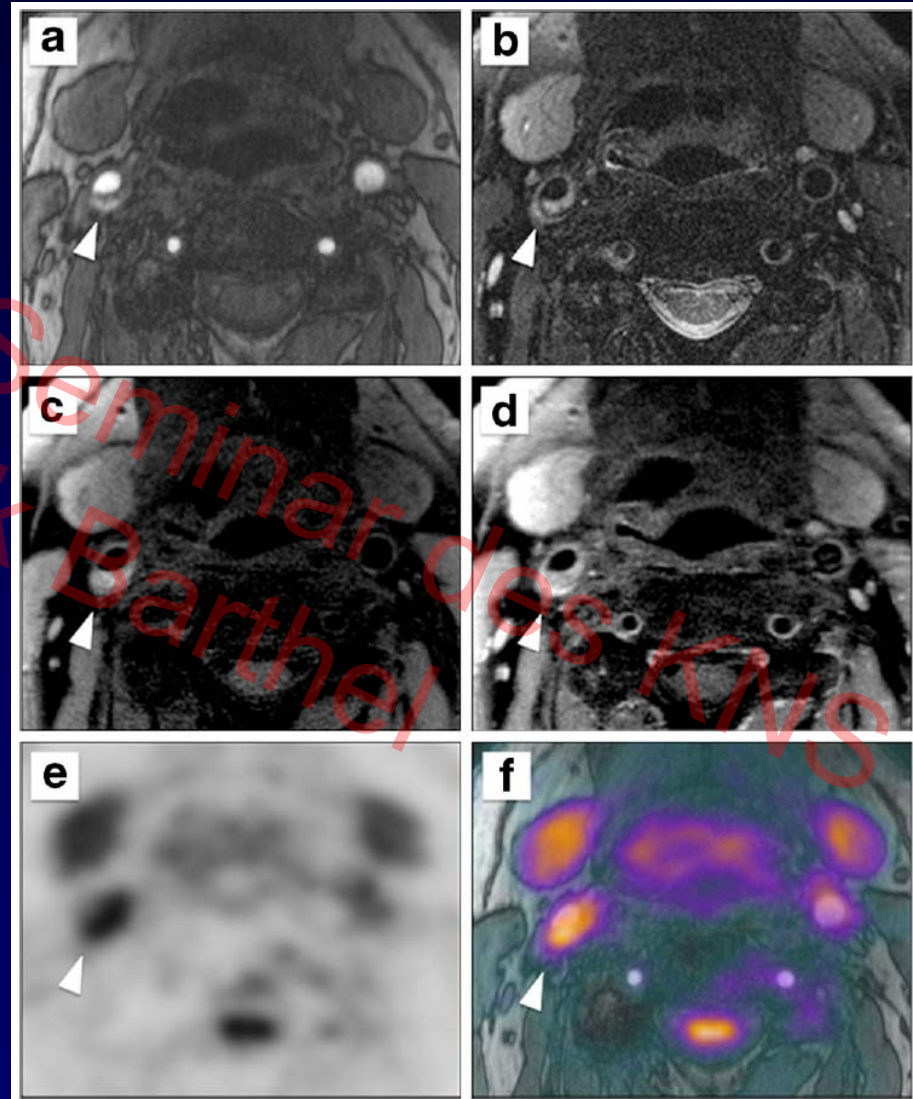
Eur J Nucl Med Mol Imaging
DOI 10.1007/s00259-015-3201-8



ORIGINAL ARTICLE

High-risk plaque features can be detected in non-stenotic carotid plaques of patients with ischaemic stroke classified as cryptogenic using combined ^{18}F -FDG PET/MR imaging

Fabien Hyafil^{1,2} · Andreas Schindler³ · Dominik Sepp⁴ · Tilman Obenhuber³ · Anna Bayer-Karpinska⁵ · Tobias Boeckh-Behrens⁶ · Sabine Höhn⁴ · Marcus Hacker⁷ · Stephan G. Nekolla^{1,8} · Axel Rominger⁹ · Martin Dichgans^{4,10} · Markus Schwaiger¹ · Tobias Saam³ · Holger Poppert⁴



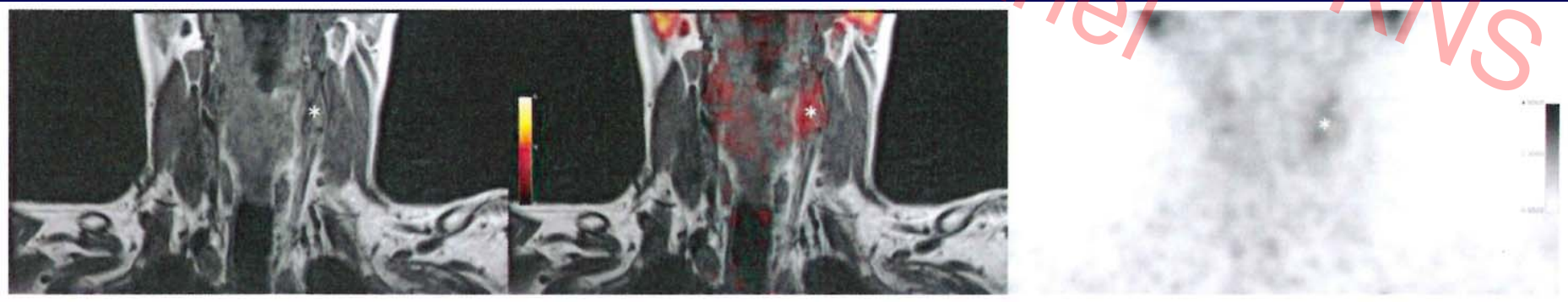
PET/MRT von Atherosklerose

Clinical and Population Studies

OPEN

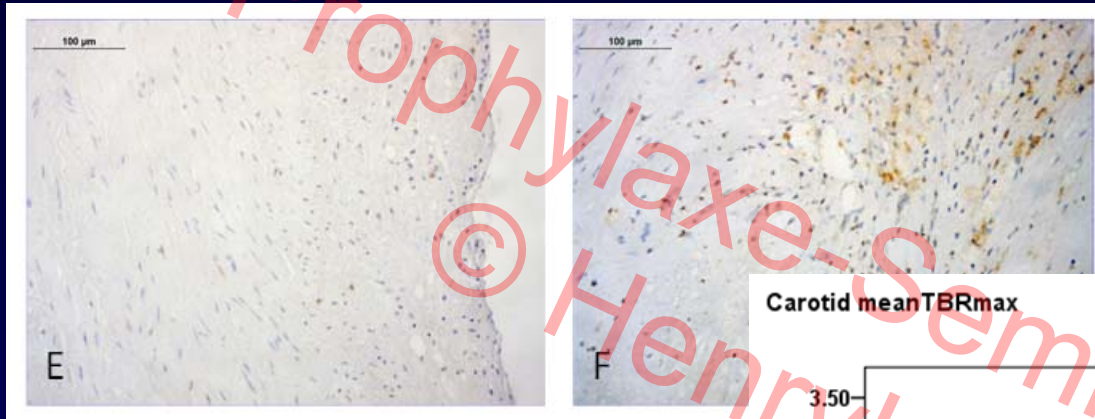
⁶⁴Cu-DOTATATE PET/MRI for Detection of Activated Macrophages in Carotid Atherosclerotic Plaques Studies in Patients Undergoing Endarterectomy

Sune Folke Pedersen, Benjamin Vikjær Sandholt, Sune Høgild Keller, Adam Espe Hansen, Andreas Ettrup Clemmensen, Henrik Sillesen, Liselotte Højgaard, Rasmus Sejersten Ripa, Andreas Kjær



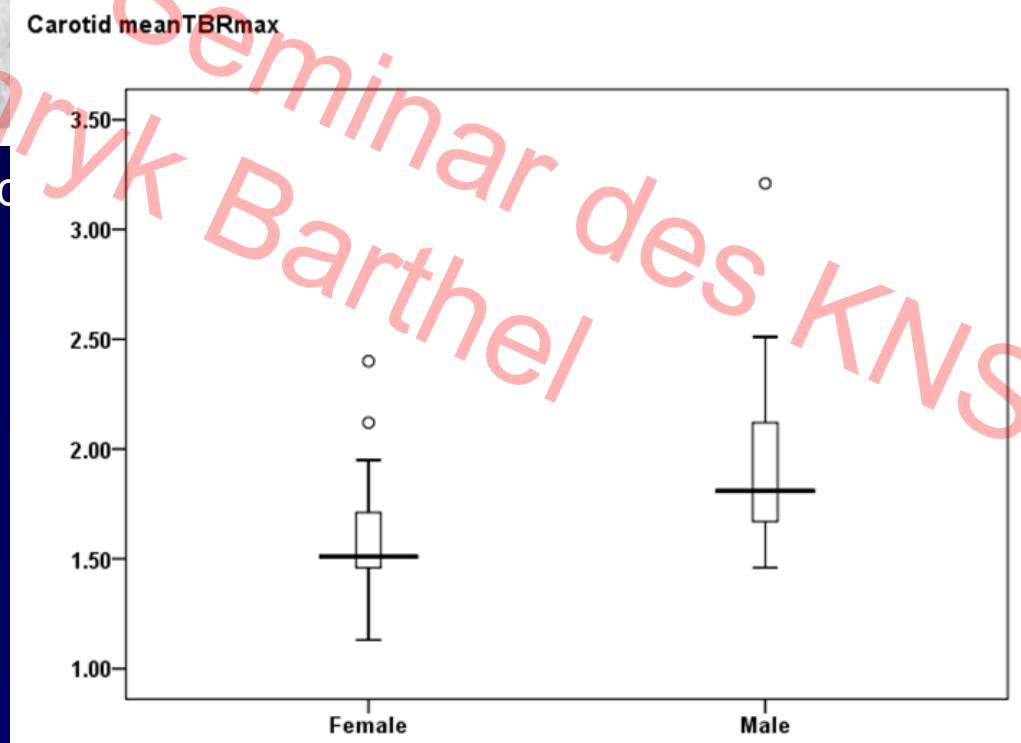
PET/MRT von Atherosklerose

Carotis-Atherosklerose



Beginnend

Fortgesch



Zusammenfassung

- ✓ Verständnis Pathophysiologie/Pathobiochemie Schlaganfall
- ✓ Hirnbildgebungs-Revolution PET → PET/MRT
- ✓ Mithilfe bei der Verbesserung von Schlaganfall-MRT und -CT
- ✓ Translationale Evaluierung neuer Schlaganfalltherapien
- ✓ Spezifische (Neuroinflammation, Atherosklerose etc.) Diagnose zerebrovaskulärer Erkrankung

Danksagung



Dorothee Saur, Josef Claßen et al.

Donald Lobsien, Karl-Titus Hoffmann et al.



Harald Möller, Toralf Mildner, Arno Villringer et al.



Peter Brust, Winnie Deuther-Conrad et al.



Nik Plesnila et al.



Björn Nitzsche, Antje Dreyer et al.



Johannes Boltze et al.



Osama Sabri et al.



Leipzig 2016

